ANATOMY AND PHYSIOLOGY OF TEMPOROMANDIBULAR JOINT

Temporomandibular joint (TMJ): Is the articulation of the condyloid process of the mandible and the inter-articular disk with the mandibular (glenoid fossa) of the temporal bone.

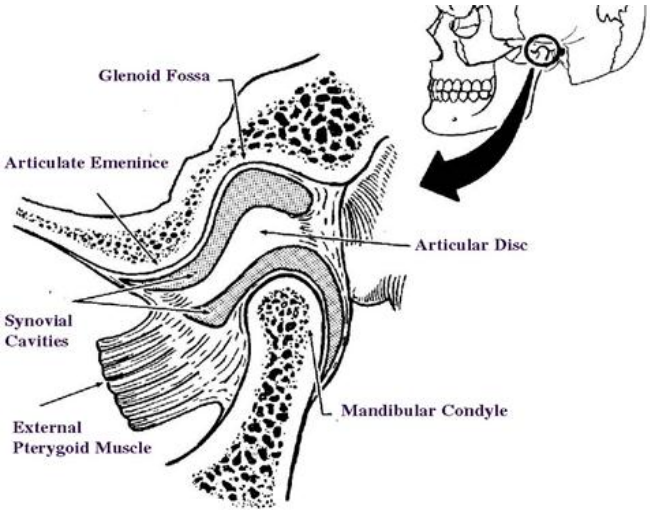

The TMJ consists of the following parts:

1. The mandibular or glenoid fossa.
2. The condyle or head of the mandible.
3. The articular disc or "Meniscus" which is found between the condyle and the glenoid fossa. It divides the synovial joint or TMJ into upper (superior) and lower (inferior) compartments.
4. Synovial cavity.

The differences between TMJ and other Joints in the body are:

1. **TMJ has an articular disc which completely divides the joint spaces into upper and lower joint compartments.**
2. **TMJ is Ginglymoarthrodial Joint.**
   a. **Hinge action (Rotation)**
   b. **Slide Action (translation)**
3. **Relationship of teeth affects the relationship of the articulating components.**
4. **The mandible is the only bone in the body hinged on both ends that is not capable of independent movement at one ends.**

The ligaments that affect the movement of the mandible consist of:

1. Temporomandibular and capsular ligaments.
2. Sphenomandibular ligament.
3. Stylomandibular ligament.

The mandibular bone has specific relationships to the bones of the cranium. The mandible is connected to the cranium at the two TMJ by the temporomandibular and capsular ligaments. The sphenomandibular and Stylomandibular ligaments also connect the bones in such a way as to limit some motions of the mandible.

The function of the ligaments is to stabilize the joints by limiting the movements, ligaments do not stretched but it could be elongated and the elongation of the ligament could compromise normal joint function.

The muscles that control the movement of the mandible may be considered in 3 groups:

1. Closing muscles.
2. Gliding muscles.
3. Opening muscle.

The masseter, temporalis and medial pterygoid muscles supply the power for pulling the mandible against the maxillae (elevating and closing mandible).

The lateral pterygoid muscles connect the mandible to the lateral ptergoid plate in such a way as to act as the steering mechanism for the mandible and act to protrude the jaw or to move it laterally.

While the muscles that depress the mandible (open) consist of four groups, suprahyoid muscle, platysma muscles, infrahyoid muscles, and lateral pterygoid muscles.

Good prosthodontic treatment bears a direct relation to the structures of the temporomandibular articulation, since occlusion is one of the most important parts of treatment of the patients with complete dentures. The TMJs affect the dentures and likewise the dentures affect health and function of the joints.

Muscular functions

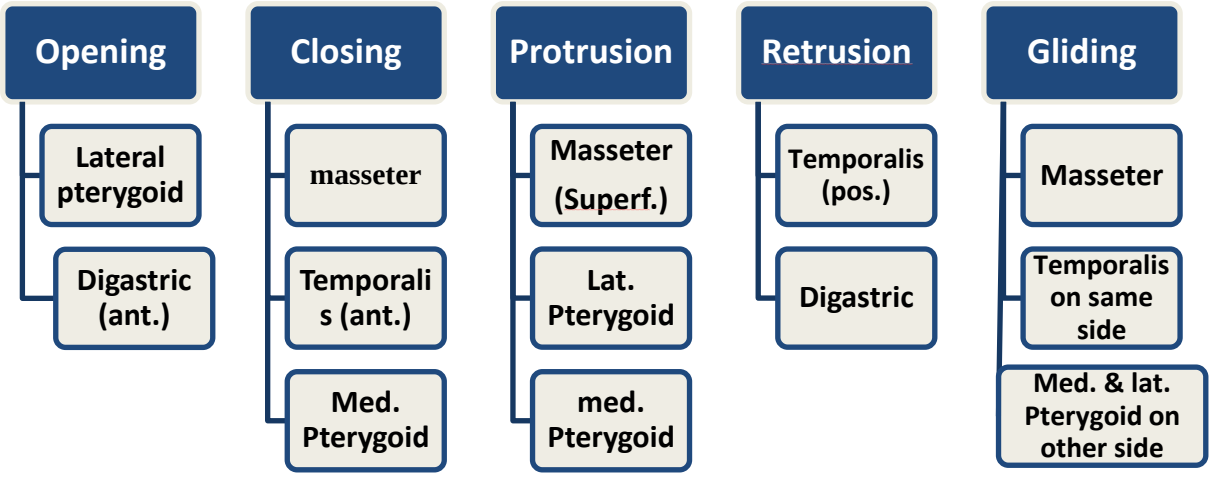

Mandibular Axes & Mandibular Movements:

Mandibular axis: There are three axes around which the mandibular movements take place in horizontal, sagittal and frontal planes. These axes include the followings:

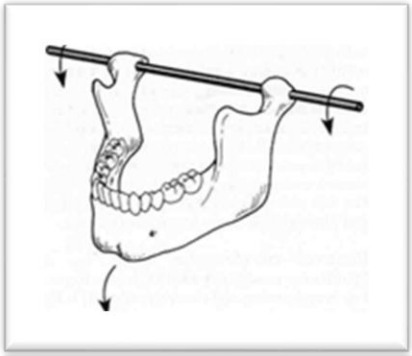

1. **Hinge axis:** or transverse horizontal axis:
   An imaginary line around which the mandible may rotate within the sagittal plane. (During the opening and closing movement).

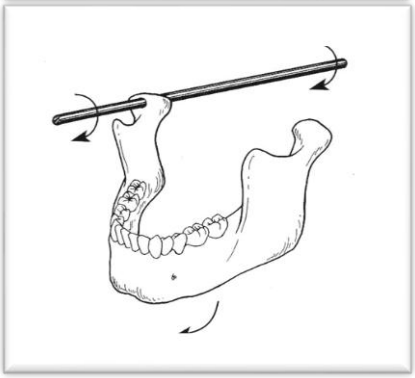

2. **Sagittal axis of the mandible :**
   An imaginary anterioposterior line around which the mandible may rotate when view in the frontal plane.

3. **Vertical axis of the mandible:**

   An imaginary line around which the mandible may rotate through the horizontal plane.

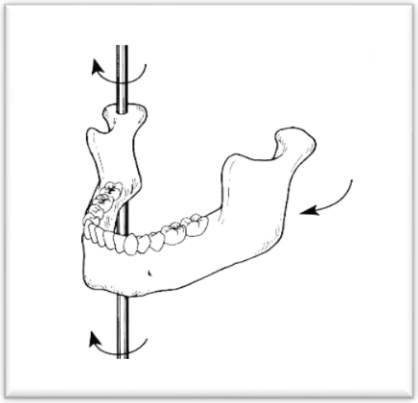

Knowledge of Mandibular movements:

1. To understand various aspects of occlusion
2. To arrange artificial teeth.
3. To select and adjust recording device articulator.

Mandibular Movements:

Classification of mandibular movement:

1. Based on the dimension involved in the movement.
2. Based on the type of movement.

1. Based on dimension

Mandibular movements are related to three planes of the skull the **horizontal, frontal, and sagittal**. The mandible rotates in each of the three planes of space. The point of intersection of the three axes is called the center of rotation.

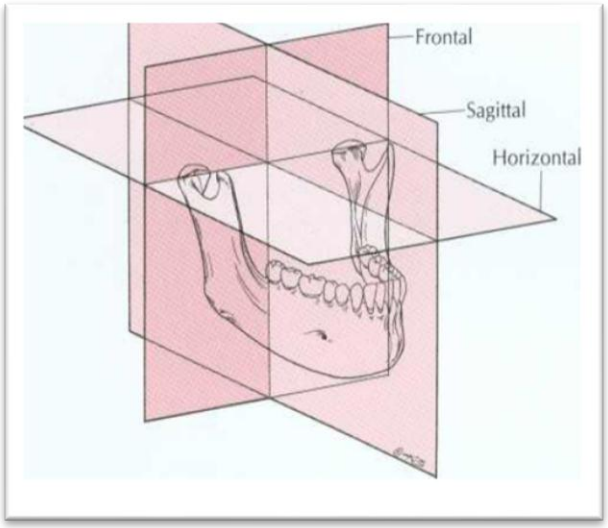

2. Based on the type of movement:

1. **Basic movements:** This movement occurs at the level of TMJ it may be divided into two types:

a- Rotational movement:

The rotational movement occurs between the condyle and the inferior surface of the articular disk, i.e. in the lower compartment of the TMJ.

b- Translatory or gliding movement:

It takes place in the upper compartment of the TMJ, i.e. between the superior surface of the articular disk and the glenoid fossa.

2- Functional movement: All mandibular movements except the terminal hinge movement, they are a combination of rotational and transitional, most frequently and are referred to as being functional movement. They are including:

- **Opening and closing movements**
- **Symmetrical forward and backward movements.**
- **Asymmetrical side wise movement or lateral movement.**